



Research Article

A RARE CASE OF RECURRENT FIXED DRUG ERUPTION AND LIP EDEMA DUE TO NORFLOXACIN AND TINIDAZOLE FIXED DOSE COMBINATION

Tripathy Ratikanta^{1*}, Pradhan Manas Ranjan²

¹Assistant Professor, Department of Pharmacology, Kalinga Institute of Medical Sciences, KIIT University, Bhubaneswar, Odisha, India

²Lecturer, Department of Pharmacology, Kalinga Institute of Medical Sciences, KIIT University, Bhubaneswar, Odisha, India

*Corresponding Author Email: dr.ratikantatripathy123@gmail.com

Article Received on: 11/01/15 Revised on: 13/02/15 Approved for publication: 18/03/15

DOI: 10.7897/2230-8407.06344

ABSTRACT

Fixed drug eruption (FDE) is one of the common manifestations of cutaneous drug induced reactions. These are mainly caused by antibiotic and analgesic preparations. Many of the fixed dose combinations available in the market are mostly used as self medication and patients suffer from drug reactions. We present a rare case of recurrent FDE and lip swelling in a patient after taking fixed dose combination of Norfloxacin and Tinidazole.

Keywords: Adverse drug reactions, Fixed drug eruption, Norfloxacin, Tinidazole

INTRODUCTION

Now a days use of Fixed Dose Combinations (FDC) is increasing and these FDCs are twice as riskier as a single drug.¹ FDC are combination of two or more active drugs in a single dosage form. Unfortunately most of FDCs used now a days in India are irrational combinations. These expose the patients to unnecessary adverse drug reactions. Most of the studies have shown that self medication of fixed dose combinations predispose for drug reactions and most combinations are from analgesics and antimicrobials drug group.² Drug induced cutaneous reactions have a wide spectrum of manifestations like urticaria, morbilliform rash, lichenoid dermatitis, stevens-johnson syndrome (SJS), fixed drug eruption (FDE).³ We present a rare case of FDE and lip swelling in a 32 years old male patient who had three recurrent attacks of the same due to self medication of Norfloxacin and Tinidazole fixed dose combination.

Case Report

We are presenting a rare case of Norfloxacin and Tinidazole fixed dose combination induced fixed drug eruption and lip edema. To start with, the patient suffered from acute gastroenteritis. So he took single tablet containing Norfloxacin and Tinidazole without consultation with any physician. After 3 hours of taking this single dose of the medication he develop fixed drug eruption over upper lip and swelling of lower lip along with itching (Figure 1). Then he visited to the department of Skin and STD regarding the problem. On examination blood pressure was 122/86, pulse was 78. There was no icterus nor pallor nor lymphadenopathy. Laboratory investigation findings were normal (Haemoglobin – 12.6, TLC – 8500 cubic per cm). A provisional diagnosis of drug induced FDE was made. Then the medication was stopped and he was prescribed with topical clobetasol ointment, levocetirizine (5 mg) tablet and coconut oil to be applied on lips. On the above treatment measures the patient recovered in five days. When the patient was enquired about the previous history of the same type of reaction he revealed

that when he took same medication six month back due to diarrhea he suffered from similar lesion at same site. Again same attack two months back due to same medication. According to the patient there was no similar manifestation when he was on other fixed dose combinations like ofloxacin and ornidazole, ofloxacin and satranidazole as well as ofloxacin alone.

DISCUSSION

Fixed drug eruption is one of the common manifestations of drug induced cutaneous reactions. Fixed drug eruption (FDE) is characterized by recurrence of localized post-inflammatory pigmentation in identical skin sites, following the oral or parenteral administration of certain drugs e.g. Tetracycline⁴, Paracetamol⁵, Cotrimoxazole⁵, Metronidazole⁵, Diclofenac⁵, Ibuprofen⁵, Tinidazole⁶, Norfloxacin⁷. Our case of Norfloxacin and Tinidazole fixed dose combination induced FDE with lip swelling is not a commonly reported ADR. Since the patient suffered from the same reaction due to same medication three times, it is a matter of concern. The reason may be wide availability of these combinations as over the counter drugs and people buy these and self medicate themselves landing upon drug reactions. Since these combinations are used in treatment of common conditions like diarrhea, so they are more prone to be used by the patients. Irrational FDCs (quinolone and nitroimidazole) continue to be heavily prescribed drugs in Gastro-intestinal tract infections etc. to cover up diagnostic imprecision and in some areas having lack of access to laboratory facilities.⁸

Causality assessment is an important part while evaluating any adverse drug reaction (ADR). This case of ADR according to Naranjo causality assessment scale⁹ is of probable category. Since this patient is exposed to the same medication and reaction is occurring three times we assume accidental rechallange¹⁰ to be positive. We were not able to do the re-challenge due to unwillingness of the patient.

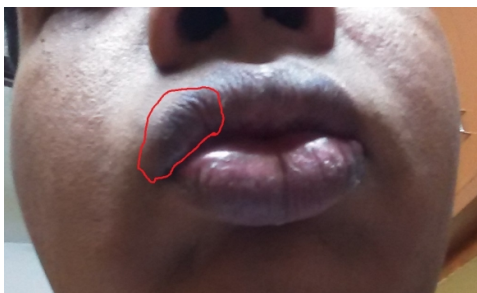


Figure 1: Fixed drug eruption on upper lip and edema of lower lip

CONCLUSION

Our case is a rare presentation of recurrent attack of drug induced FDE. Norfloxacin and Tinidazole fixed dose combination is widely available as over the counter medication. Since this reaction was due to self medication, the physician as well as the public should be educated regarding the hazards of drug reaction especially of self medication.

REFERENCES

1. Gautam CS, Saha L. Fixed dose drug combinations (FDCs): Rational or irrational: a view point. Br J Clin Pharmacol 2007; 65(5):795-6. <http://dx.doi.org/10.1111/j.1365-2125.2007.03089.x>
2. Gajendra *et al.* Self medication of antimicrobials and exploring awareness of ADRs to self medication of antimicrobials in Pune, Maharashtra, India. World Journal of Pharmaceutical Research 2014; 3(4): 726-733.
3. www.emedicine.medscape.com/article/1336702-overview.
4. Delaney TJ. Tetracycline induced fixed drug eruptions. Br. J. Dermatol 1970; 83: 357-358. <http://dx.doi.org/10.1111/j.1365-2133.1970.tb15715.x>
5. Pasricha JS. Drugs causing fixed eruptions. Br. J. Dermatol 1979; 100: 183. <http://dx.doi.org/10.1111/j.1365-2133.1979.tb05559.x>
6. M Jafferany, TS Haroon. Tinidazole induced fixed drug eruption. Journal of Pakistan medical association; 1987. www.researchgate.net/.../004635285195217127000000.pdf
7. Sarwar S, Hossain D. Fixed dose combination and disease management. Int. Res. J. Pharm 2012; 3(11): 17-21.
8. Naranjo CA, Busto U, Sellers EM, Sandor P, Ruiz I, Roberts EA *et al.* A method for estimating the probability of adverse drug reactions. Clin Pharmacol Ther 1981; 30: 239-45. <http://dx.doi.org/10.1038/clpt.1981.154>
9. <http://livertox.nih.gov/Narajo.html>

Cite this article as:

Tripathy Ratikanta, Pradhan Manas Ranjan. A rare case of recurrent fixed drug eruption and lip edema due to Norfloxacin and Tinidazole fixed dose combination. Int. Res. J. Pharm. 2015; 6(3):204-205 <http://dx.doi.org/10.7897/2230-8407.06344>

Source of support: Nil, Conflict of interest: None Declared