**Research Article**



**INTERNATIONAL RESEARCH JOURNAL OF PHARMACY**

www.irjponline.com

**ISSN 2230-8407 [LINKING]**

# A Comparison of Erector Spinae Plane Block and Oblique Subcostal Transversus Abdominis Plane (TAP) Block for Postoperative Analgesia in Laparoscopic Cholecystectomy: A Randomized Controlled Study

**Dr. Akshita Verma[1*], Dr. Anurag Srivastava[2], Dr. Ansika Yadav[3], Dr. Prem Kumari Bhamri[4], Dr. G. P. Singh[5]**

[1*]Junior resident, Dept. of Anaesthesiology, T. S. Mishra Medical College & Hospital, Lucknow (U.P)

[2]Associate Professor, Dept. of Anaesthesiology, Dr. RML Institute of Medical Sciences, Lucknow (U.P)

[3]Assistant Professor, Dept. of Anaesthesiology, T. S. Mishra Medical College & Hospital, Lucknow (U.P)

[4]Professor, Dept. of Anaesthesiology, T. S. Mishra Medical College & Hospital, Lucknow (U.P)

[5]Professor & Head, Dept. of Anaesthesiology, T. S. Mishra Medical College & Hospital, Lucknow (U.P)

**Corresponding Author**

Dr. Akshita Verma[1]

Email id: drakshitaverma@gmail.com

How to cite: Verma A, Srivastava A, Yadav A, Bhamri PK, Singh GP, A Comparison of Erector Spinae Plane Block and Oblique Subcostal TAP Block for Postoperative Analgesia in Laparoscopic Cholecystectomy: A Randomized Controlled Study 2026,17:5:19-24

Doi: http://doi.org/10.56802/irjp.2026.v17.i5.pp19-24

==========

**ABSTRACT**

**Background:** Effective postoperative pain control following laparoscopic cholecystectomy is essential for early recovery and improved patient satisfaction. Ultrasound-guided erector spinae plane block (ESPB) and oblique subcostal transversus abdominis plane block (OSTAPB) are commonly used regional analgesic techniques; however, comparative evidence regarding their efficacy remains limited.

**Materials & Methods:** This prospective randomized comparative study was conducted among 60 patients undergoing elective laparoscopic cholecystectomy under general anaesthesia. Patients were randomly allocated into two groups: Group E received ultrasound-guided ESPB (n=30) and Group O received ultrasound-guided OSTAPB (n=30). The primary outcome was time to first rescue analgesia. Secondary outcomes included static and dynamic Visual Analogue Scale scores and total tramadol consumption during the first 24 postoperative hours.

**Results:** The mean time to first rescue analgesia was significantly longer in the ESPB group compared to the OSTAPB group (9.58 ± 1.2 vs 8.09 ± 1.0 hours; $p<0.001$). Static VAS scores were significantly lower in the ESPB group from 1 hour onwards, while dynamic VAS scores were significantly lower from 30 minutes onwards up to 24 hours postoperatively ($p<0.001$). Total postoperative tramadol consumption was significantly reduced in the ESPB group compared to the OSTAPB group (6.67 ± 17.2 mg vs 61.67 ± 44.8 mg; $p<0.001$).

**Conclusion:** Ultrasound-guided ESPB provided superior postoperative analgesia with prolonged analgesic duration, lower pain scores, and reduced opioid consumption compared to OSTAPB in patients undergoing laparoscopic cholecystectomy.

**Keywords:** Erector spinae plane block, Transversus abdominis plane block, Laparoscopic cholecystectomy, Postoperative analgesia, Visual Analogue Scale.

## INTRODUCTION

Patients who undergo surgery experience excessive pain during their recovery period because doctors lack the ability to control their pain, which leads to negative effects on their recovery and decreased patient satisfaction according to Niyonkuru and colleagues from 2025. The International Association for the Study of Pain defines pain as an unpleasant sensory and emotional experience that occurs with actual or possible tissue damage. Patients who experience unmanaged postoperative pain will take a longer time to move around the hospital while developing more severe health problems that require extended hospital stays according to research by Raja et al.,2020.

Laparoscopic cholecystectomy stands as the most commonly executed abdominal surgical procedure throughout the globe. Patients who undergo the procedure will experience moderate to severe postoperative pain because the surgery involves both somatic and visceral and referred pain mechanisms (Shrestha et al., 2024). Clinicians need effective solutions for pain management because such solutions will improve recovery results while delivering better patient outcomes.

Multimodal analgesia creates targeted pain relief solutions by using regional anaesthesia techniques that produce fewer body wise side effects, according to research by Tornero et al.,2017. The oblique subcostal transversus abdominis plane block provides analgesia to the anterior abdominal wall, whereas the erector spinae plane block has gained popularity for its potential to provide both somatic and visceral analgesia (Hou et al., 2024).

Anaesthetists use both techniques for postoperative pain control after laparoscopic cholecystectomy, yet there exists insufficient data that shows which method works better in our area. Hence, this study was conducted to compare the effects of erector spinae plane block and oblique subcostal transversus abdominis plane block on patients who underwent laparoscopic cholecystectomy through their rescue analgesia time, first postoperative pain scores, and total pain relief medication intake.

## MATERIALS & METHODS

This prospective randomized comparative study was conducted in the Department of Anaesthesiology at T.S.M. Medical College and Hospital, Amausi, Lucknow, over a period of 18 months after approval from the Institutional Ethics Committee and obtaining written informed consent from all participants.

A total of 60 patients aged 18–65 years, belonging to American Society of Anaesthesiologists (ASA) physical status I and II, with BMI between 18–30 kg/m² and scheduled for elective laparoscopic cholecystectomy under general anaesthesia were included. Patients with significant systemic illness, chronic opioid use, previous abdominal surgery or trauma, allergy to local anaesthetics, refusal to participate, or conversion to open surgery were excluded.

Sample size was calculated using previously published data (Rafi AN, 2001) based on the difference in postoperative analgesic requirement between groups, with 95% confidence interval and 90% power, yielding 30 patients in each group.

Patients were randomized into two groups using a computer-generated randomization sequence and sealed envelope technique:

1. Group E (n=30): Ultrasound-guided erector spinae plane block (ESPB)
2. Group O (n=30): Ultrasound-guided oblique subcostal transversus abdominis plane block (OSTAPB)

General anaesthesia was induced with intravenous propofol (2 mg/kg), fentanyl (2 µg/kg), and vecuronium (0.1 mg/kg). Intravenous paracetamol (1 g) and diclofenac (75 mg) were administered intraoperatively. Anaesthesia was maintained using inhalational agents under standard monitoring.

Following surgery and before extubation, bilateral ultrasound-guided blocks were administered by experienced anaesthesiologists using 20 mL of 0.25% bupivacaine on each side. In Group E, ESPB was performed at the T7 transverse process level using an in-plane approach. In Group O, OSTAPB was performed in the fascial plane between the rectus abdominis and transversus abdominis muscles.

Postoperative pain assessment was performed using the Visual Analogue Scale (VAS; 0=no pain, 10=worst imaginable pain). Static and dynamic VAS scores were recorded at predefined intervals up to 24 hours postoperatively. Rescue analgesia with intravenous tramadol 50 mg was administered when VAS ≥4.

The primary outcome was time to first rescue analgesia. Secondary outcomes included static and dynamic VAS scores and

total tramadol consumption during the first 24 postoperative hours.

Data were analyzed using IBM SPSS Statistics version 27.0. Continuous variables were expressed as mean ± standard deviation and compared using the independent t-test, A p-value <0.05 was considered statistically significant.

**RESULT**

**Table 1. Comparison of time to first rescue analgesia between groups**

| Parameter | ESPB (n=30) | OSTAPB (n=30) | T-value/ df | p-value |
|---|---|---|---|---|
| Time to first rescue analgesia (hours) | 9.58 ± 1.2 | 8.09 ± 1.0 | 5.23/ 58 | **<0.001** |

The mean time to first rescue analgesia was significantly longer in the ESPB group compared to the OSTAPB group (table 1), indicating prolonged analgesic duration with ESPB.

**1. Visual Analogue Scale (VAS) Scores**

**Static VAS**

**Table 2. Comparison of static VAS scores at different time intervals**

| Time Interval | ESPB | OSTAPB | t-value | p-value |
|---|---|---|---|---|
| **0 hour** | 0.83 ± 0.56 | 0.95 ± 0.60 | 0.80 | 0.426 |
| **30 min** | 1.08 ± 0.55 | 1.30 ± 0.68 | 1.38 | 0.173 |
| **1 hour** | 1.08 ± 0.50 | 1.94 ± 0.55 | 6.32 | **<0.001** |
| **4 hours** | 1.85 ± 0.67 | 3.03 ± 0.72 | 6.57 | **<0.001** |
| **8 hours** | 2.06 ± 0.67 | 2.97 ± 0.85 | 4.63 | **<0.001** |
| **12 hours** | 1.82 ± 0.72 | 3.01 ± 0.68 | 6.57 | **<0.001** |
| **24 hours** | 1.98 ± 0.52 | 3.02 ± 0.60 | 7.18 | **<0.001** |

The comparison of static VAS scores between the ESPB and OSTAPB groups demonstrated comparable pain scores during the immediate postoperative period at 0 hour and 30 minutes, with no statistically significant difference observed (p>0.05). However, from 1 hour onwards, the ESPB group showed significantly lower static VAS scores compared to the OSTAPB group at all subsequent time intervals up to 24 hours (p<0.001) as shown in Table 2.

**Dynamic VAS**

**Table 3. Comparison of dynamic VAS scores at different time intervals**

| Time Interval | ESPB | OSTAPB | t-value | p-value |
|---|---|---|---|---|
| **0 hour** | 0.88 ± 0.62 | 0.98 ± 0.60 | 0.64 | 0.528 |
| **30 min** | 1.10 ± 0.60 | 1.40 ± 0.54 | 2.03 | **0.046** |
| **45 min** | 0.98 ± 0.45 | 2.12 ± 0.62 | 8.14 | **<0.001** |
| **2 hours** | 1.04 ± 0.66 | 2.07 ± 0.53 | 6.65 | **<0.001** |
| **8 hours** | 1.95 ± 0.64 | 3.25 ± 0.64 | 7.87 | **<0.001** |
| **12 hours** | 2.00 ± 0.54 | 3.13 ± 0.63 | 7.44 | **<0.001** |
| **24 hours** | 2.10 ± 0.65 | 3.00 ± 0.65 | 5.36 | **<0.001** |

Dynamic VAS scores were similar at baseline but became significantly lower in the ESPB group from 30 minutes onwards, with highly significant differences observed from 45 minutes to 24 hours (p < 0.001) depicted in Table 3.

**2. Total Opioid (Tramadol) Consumption**

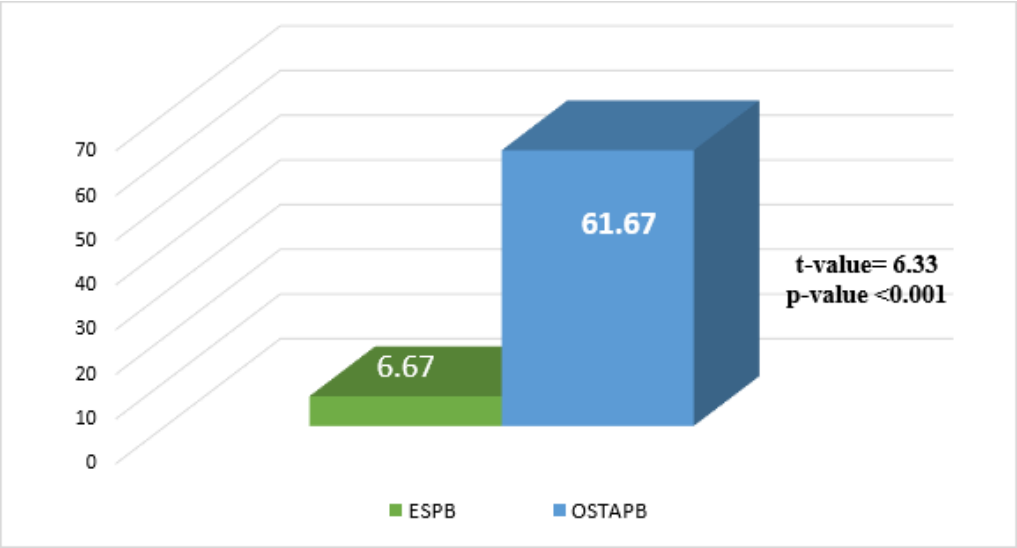


**Figure 1: Comparison of total tramadol consumption in 24 hours**

The total tramadol consumption during the first 24 postoperative hours was significantly lower in the ESPB group (6.67 ± 17.2 mg) compared to the OSTAPB group (61.67 ± 44.8 mg) ($p < 0.001$), demonstrating the superior opioid-sparing effect of ESPB as shown in Figure 1.

**DISCUSSION**

The study results showed that ESPB delivered better pain relief after surgery than OSTAPB. The present results match the study results of Dharani M. et al., who showed that the ESPB group required rescue analgesics after laparoscopic cholecystectomy for 12.2 ± 5.6 hours while the OSTAP group needed them after 6.6 ± 2.84 hours. The ESPB group showed lower postoperative pain scores, which led to decreased tramadol use, therefore.

Ultrasound-guided ESPB decreased postoperative tramadol use and pain levels, which reached statistical significance when compared to OSTAP block in patients who underwent laparoscopic cholecystectomy, according to the findings of Altıparmak et al. The study reported that the ESPB group used 139.1 ± 21.9 mg of tramadol after surgery, while the OSTAP group used 199.4 ± 27.7 mg ($p < 0.001$), which demonstrated the superior opioid-sparing effect of the present study.

Engineer et al. found that the ESPB group after laparoscopic cholecystectomy showed significantly lower postoperative tramadol consumption when compared to the OSTAP group. The present study found that the ESPB group showed lower VAS scores from 1 hour until 24 hours after surgery, while they showed lower dynamic VAS scores starting from 30 minutes onward. Ruchi Verma et al. found that patients who received ESPB after laparoscopic cholecystectomy showed significantly lower static and dynamic VAS scores. The ESPB group required less intraoperative fentanyl, and they could start walking sooner after surgery.

Mounika et al. found that the ESPB group had lower VAS scores during the first day of their postoperative recovery. The ESPB group showed VAS scores under 4 for 24 hours, while patients who received OSTAP block needed extra opioid doses throughout the day.

Kadlimatti et al. showed that ESPB provided longer pain relief, which lasted 671.39 ± 41.77 minutes, than subcostal TAP block, which lasted 535.50 ± 230.28 minutes ($p < 0.001$), in patients who underwent laparoscopic cholecystectomy.

The study by Kamel et al. found that ESP block resulted in lower VAS scores and a later first rescue analgesia time and less postoperative opioid use when compared to TAP block assessment after abdominal hysterectomy. The study results show that ESPB provides better postoperative pain relief and reduces opioid consumption more effectively than OSTAPB according to existing research.

**CONCLUSION & RECOMMENDATIONS**

Ultrasound-guided erector spinae plane block (ESPB) provided superior postoperative analgesia compared to oblique subcostal transversus abdominis plane block (OSTAPB) in patients undergoing laparoscopic cholecystectomy, as evidenced by prolonged duration of analgesia, lower static and dynamic Visual Analogue Scale scores, and significantly reduced postoperative tramadol consumption during the first 24 postoperative hours. Further large-scale multicentric studies with longer follow-up are recommended to validate these findings and assess additional outcomes such as patient satisfaction, early ambulation, and long-term recovery.

## CONFLICT OF INTEREST

Nil

## REFERENCES

1. Altıparmak, B., Toker, M. K., Uysal, A. I., Kuşçu, Y., & Demirbilek, S. G. (2019). Ultrasound-guided erector spinae plane block versus oblique subcostal transversus abdominis plane block for postoperative analgesia of adult patients undergoing laparoscopic cholecystectomy: Randomized, controlled trial. Journal of Clinical Anesthesia, 57, 31–36. https://doi.org/10.1016/j.jclinane.2019.03.012
2. Dharani, M., Udayakumar, G. S., Sivakumar, S. K., Sethuraman, R. M., & Narayanan, V. (2025). Comparison of ultrasound-guided erector spinae plane block and oblique subcostal transversus abdominis plane block for postoperative analgesia after laparoscopic cholecystectomies: A prospective randomized controlled trial. Cureus, 17(9), e93364. https://doi.org/10.7759/cureus.93364
3. Engineer, S. R., Devanand, A., & Kulkarni, M. (2022). Comparative study of the efficacy of ultrasound-guided erector spinae block and oblique subcostal transversus abdominis plane block for postoperative analgesia after laparoscopic cholecystectomy. Ain-Shams Journal of Anesthesiology, 14, 84. https://doi.org/10.1186/s42077-022-00285-4
4. Hou, P., Liu, W., Chen, R., Mi, H., Jia, S., & Lin, J. (2024). Comparison of erector spinae plane block and transverse abdominis plane block in postoperative recovery after laparoscopic colorectal surgery: A randomized, double-blind, controlled trial. Perioperative Medicine, 13(1), 116. https://doi.org/10.1186/s13741-024-00475-8
5. Kadlimatti, D. V., Iqbal, M. S., Nousheen, S. A., Harsoor, S. S., Vijaymohan, P. A., Harshitha, K., & Hiremath, A. J. (2025). Assessment of efficacy of erector spinae plane block versus subcostal transversus abdominis plane block for postoperative pain management in laparoscopic cholecystectomy under general anaesthesia: A randomized controlled trial. Journal of Pharmacy and Bioallied Sciences, 17(Suppl 3), S2268–S2270. https://doi.org/10.4103/jpbs.jpbs_1117_25
6. Kamel, A. A. F., Amin, O. A. I., & Ibrahem, M. A. M. (2020). Bilateral ultrasound-guided erector spinae plane block versus transversus abdominis plane block on postoperative analgesia after total abdominal hysterectomy. Pain Physician, 23(4), 375–382.
7. Mounika, V., Sahu, L., Mishra, K., & Mohapatra, P. S. (2023). A comparative evaluation of post-operative pain management using erector spinae plane block and oblique transverse abdominis plane block in patients undergoing laparoscopic cholecystectomy. Cureus, 15, e35750. https://doi.org/10.7759/cureus.35750
8. Niyonkuru, E., Iqbal, M. A., Zhang, X., & Ma, P. (2025). Complementary approaches to postoperative pain management: A review of non-pharmacological interventions. Pain Therapy, 14(1), 121–144. https://doi.org/10.1007/s40122-024-00688-1
9. Rafi, A. N. (2001). Abdominal field block: A new approach via the lumbar triangle. Anaesthesia, 56(10), 1024–1026. https://doi.org/10.1046/j.1365-2044.2001.02279-40.x
10. Raja, S. N., Carr, D. B., Cohen, M., Finnerup, N. B., Flor, H., Gibson, S., Keefe, F. J., Mogil, J. S., Ringkamp, M., Sluka, K. A., Song, X. J., Stevens, B., Sullivan, M. D., Tutelman, P. R., Ushida, T., & Vader, K. (2020). The revised International Association for the Study of Pain definition of pain: Concepts, challenges, and compromises. Pain, 161(9), 1976–1982. https://doi.org/10.1097/j.pain.0000000000001939
11. Shrestha, B. B., Lakhe, G., & Ghimire, P. (2024). Postoperative pain after laparoscopic cholecystectomy in a tertiary care center: A descriptive cross-sectional study. JNMA Journal of Nepal Medical Association, 62(276),

502–506. https://doi.org/10.31729/jnma.8719

12. Tornero Tornero, C., Fernández Rodríguez, L. E., & Orduña Valls, J. (2017). Multimodal analgesia and regional anaesthesia. Revista Española de Anestesiología y Reanimación, 64(7), 401–405. https://doi.org/10.1016/j.redar.2017.01.008
13. Verma, R., Srivastava, D., Saxena, R., Singh, T. K., Gupta, D., Agarwal, A., & Mishra, P. (2020). Ultrasound-guided bilateral erector spinae plane block for postoperative analgesia in laparoscopic cholecystectomy: A randomized controlled trial. Anesthesia: Essays and Researches, 14, 226–232. https://doi.org/10.4103/aer.AER_41_20