



Research Article

KARAYA POWDER AND ITS EFFECT ON DIABETIC FOOT ULCER

Thenmozhi P^{1*}, P. Mangala Gowri², Aleena Meetyal A³, Annie Cinthiya K³, Ammu F³, Anandhi S³

¹Associate Professor, Saveetha College of Nursing, SIMATS, Chennai, India

²Principal, Saveetha College of Nursing, SIMATS, Chennai, India

³Student, Saveetha College of Nursing, SIMATS, Chennai, India

*Corresponding Author Email: thenmozhi.sethu@gmail.com

Article Received on: 21/08/18 Approved for publication: 28/09/18

DOI: 10.7897/2230-8407.0910245

ABSTRACT

Background of the study: The management of diabetic foot ulcers is a major therapeutic challenge. The aim of the study is to investigate the effectiveness of karaya powder on diabetic foot ulcer healing thereby reduce the burden of care and improve the quality of life. Materials and Methods: Pre-experimental research design was adopted to conduct the study with 30 samples who met the inclusion criteria in Saveetha Medical College and Hospital. Samples were allocated into experimental group (n=30) and control group (n=30) by convenience sampling technique. The demographic questionnaire was completed at the beginning of the study. Pre-test was conducted by using Bates-Jensen Wound Assessment Tool for the both the groups. Karaya powder was administered after cleaning the wound aseptically from the same day onwards for 3 weeks to the experimental group, whereas control group received routine care of the hospital dressing. Post-test was conducted at the end of third week for the both the group. Data were analyzed using SPSS. Results: There was a difference in the pre-test (17.60±2.16) and post-test (13.6±2.44) mean value in the experimental group and found statistically significant at the level of p<0.001. It was also observed the significant difference between the experimental and control group. Conclusion: The finding of the study concluded that karaya dressing has proved the beneficial effect in healing of diabetic foot ulcers and can be practiced in treating diabetic foot ulcer after the replication of same study in different setting with large sample.

Keywords: Diabetic foot ulcer, karaya powder, diabetes mellitus, wound healing.

INTRODUCTION

Diabetic foot is one of the most significant and devastating complications of diabetes. It is defined as a foot affected by ulceration that is associated with neuropathy and / or peripheral arterial disease of the lower limb in a patient with diabetes. The prevalence of diabetic foot ulcer in the diabetic population is 4–10%. The condition is more frequent in older patients. It is estimated that about 5% of all patients with diabetes present with a history of foot ulceration. The lifetime risk of diabetic patients developing this complication is 15%¹.

The majority (60–80%) of foot ulcers will heal, while 10–15% of them will remain active, and 5–24% of them will finally lead to limb amputation within a period of 6–18 months after the first evaluation. Neuropathic wounds are more likely to heal over a period of 20 weeks, while neuroischemic ulcers take longer and will more often lead to limb amputation². It has been found that 40–70% of all nontraumatic amputations of the lower limbs occur in patients with diabetes. Furthermore, many studies have reported that foot ulcers precede approximately 85% of all amputations performed in diabetic patients³. Studies show severity of diabetic foot ulcer is the strongest significant risk factor of amputation of diabetic patients. In developed countries 1 in every 6 people with diabetes will have ulcer during life time. The risk is even higher in developing countries⁴.

People with diabetes often develop diabetic neuropathy due to several metabolic and neurovascular factors. Other risk factors for foot ulceration include a previous history of foot ulceration or amputation, visual impairment, diabetic nephropathy, poor glycemic control, and cigarette smoking. Some studies have shown that foot ulceration is more common in men with diabetes

than in women⁵. Social factors, such as low socioeconomic status, poor access to healthcare services, and poor education are also proven to be related to more frequent foot ulceration⁶. India has the highest number of people with diabetes in the world. Diabetic foot care is one of the most ignored aspects of diabetes care in India. Due to social, religious, and economic compulsions, many people walk barefoot. Poverty and illiteracy lead to usage of inappropriate foot wear and late presentation of foot lesions⁷.

Manifestations of diabetic foot ulcer range from simple to highly complex, including limb amputations and life-threatening infections. Diabetic foot lesions have significant health and socioeconomic problems holding adverse effects on the quality of life of the patient and imposing a heavy economic burden on the patient's family. Foot ulcers significantly contribute to morbidity and mortality of patients with diabetes mellitus. The diabetic patients with foot ulcers require long-term hospitalization and carry the risk of limb amputation. The management of diabetic foot ulcers is a major therapeutic challenge. There are pharmacological and non-pharmacological strategies and treatments are available to reduce the burden of care in an efficient and cost-effective way. Different strategies including honey dressings, medicated dressings, povidone iodine dressings, platelet rich plasma dressings, saline dressings, vacuum dressings and papaya dressings are available in the management of diabetic foot. Investigators found that karaya powder dressing is one of the best effective ways of treating the patients with chronic ulcer during review the literature.

Karaya, natural hydrocolloid, medicinal remedy and has unique skin care properties. Karaya Gum is an extract obtained from the tree of sterculia genus in India. It consists of acid polysaccharide sugars such as galactose, galacturonic acid and rhamnose⁸. It

absorbs moisture or exudates skin prior to placing a skin barrier on skin thereby used in the treatment of wounds and sores. Gum karaya is mostly used as an ingredient in the preparation of emulsions, lotions, denture fixative powders, bulk laxatives, as a pulp binder in the preparation of thin papers and suspension properties⁹. It worked by increasing the granulation and improves healing even in resistant or chronic bedsores. It is also found that Karaya gum comprise effective amounts of antimicrobials, anti-inflammatories, and antihistamines, to provide an ulcer medication which prevents secondary infections and promotes healing while providing immediate relief from pain. Gum karaya is used in powder form for wound and sores. It is suited for stabilizing low pH emulsions, such as sauces and dressings due to its acid stability, high viscosity, and suspension properties¹⁰. The gum particles do not dissolve but absorb water and swell extensively to more than 60 times the original volume due to the presence of acetyl groups in its structure. From chemistry point of view karaya will absorb water quickly and forms a gum. It can absorb as much as 100 times its weight in water. With higher concentrations of water, karaya forms a gel or paste that can be used to comfortable and safely smooth out rough and uneven skin¹¹.

Hence the investigator felt the need to conduct the study aimed to determine the effectiveness of Karaya powder application on wound healing of diabetic foot ulcer. The finding of this study would prevent the occurrence of secondary infection, gangrene formation and amputation with cost effective among patients with diabetic foot ulcer.

MATERIALS AND METHODS

Quasi experimental one group per-test and post-test design was adopted to conduct the study among patients with diabetic foot ulcer. It was conducted at Saveetha Medical College hospital Chennai, after obtaining formal permission from the hospital authority. Study was ethically cleared with reference to the 009/04/2018/IEC/SIMATS dated 12h April 2018. The investigators explained about the study and obtained the informed consent from the participants. The samples who included in the study were patients with age group between 45 to 65 years of both the sex, meeting the Wagner's ulcer grade II and III and were willing to participate in the study. Sixty patients with diabetic foot ulcer were selected for the study by using a convenience sampling technique. Experimental group (n=30) were selected from male & female surgical wards. Demographic variables and clinical variables were collected by using structured questionnaire. The pre-test assessment was done by using Bates-Jensen wound assessment tool. The experimental group was received karaya powder application. Karaya powder was sprinkled over the wound after cleaned the aseptically with betadine and normal saline. Wound covered with sterile gauze piece. It was applied for 3 weeks. Dressing was changed every 24 hours for three weeks and the control group were continued the routine care of the hospital. The posttest assessment was done at the end of third week by using Bates-Jensen wound assessment tool for both experimental and control groups. Data were analyzed by descriptive and inferential statistics using SPSS statistical package.

RESULTS

The present study findings observed that around 40% of the participants were in the age group of 56-60 years and majority of them were male. 100% of the participants had been suffering from Type II diabetes mellitus with regular health check-up and on the treatment of both insulin and oral hypoglycemic agents. More than 50% of them had 5-10 years duration of diabetes mellitus, none of them had no history of peripheral vascular disease and around 13(86.66%) with poor self-care practices of foot care.

Regarding the level of wound healing in pre-test of both experimental and control group, out of 30 samples 24(80%) of them had wound regeneration and six (20%) of them had wound degeneration, similarly in control group all of them 30(100%) had wound regeneration and none of them had tissue health in both experimental and control group as shown in figure 1.

Within the experimental, the effectiveness of karaya powder application dressing was analyzed by paired 't' test revealed that there was a difference in the pre-test (17.60±2.16) and post-test (13.6±2.44) mean value in the experimental group and found statistically significant at the level of $p < 0.001$ revealing that the intervention is beneficial in wound healing.

Unpaired 't' test was used to compare the level of wound healing between the control and experimental group revealed the post-test mean 13.60 with 2.44SD, whereas in control group it was 19.60 with SD of 2.52. It was also proved that there was statistically ($p < 0.001$) significant difference between the experimental and control groups in level of wound healing.

DISCUSSION

Foot complications are common in diabetic patients and are considered one of the most expensive diabetes complications to treat. The management of patients with diabetic foot ulcer is complex to plan for a proper care. The primary responsible for health care provider is to assess the wound healing in order to provide the effective care to avoid amputations and promote wellbeing and quality of life of the patients with diabetic foot ulcer. The present study finding revealed that in the pretest almost more than 80% of them had wound regeneration and none of them had healthy tissue in both experimental and control group, which shows that patients who were admitted with diabetic foot ulcer having same score. Though the patients are in regular treatment of diabetes mellitus, they had the foot ulcer. One of the reasons might be poor practices of self-care activities of foot care. If left untreated the diabetic foot, it leads to gangrene and amputation.

The present study intensively analyzed the karaya powder application on diabetic wound ulcer healing and found statistically significant in improving wound healing in experimental group. There are limited studies are available regarding the effectiveness of karaya powder application. But none of studies have been done for diabetic foot ulcer. Singh and Pal (2008), had studied and reported that karaya powder wound dressing could have the double potential action, first due to inherent antimicrobial nature of the sterculia gum and second due to the controlled release of antimicrobial agent from the hydrogel matrix in the controlled and sustained manner¹³. Baljit Singh et al, carried out the modification of sterculia gum to develop the novel wound dressing for the delivery of antimicrobial agent (tetracycline hydrochloride). The drug release behaviour of sterculia crosslinked PVA (sterculia-clPVA) hydrogels were studied in the simulated wound fluid. Researchers also studied the use of karaya gum as a potential thickening agent and as a carrier for antidiarrhoeal drug in combination with poly vinyl pyrrolidone (PVP)¹⁴. Holister stated that Featuring Karaya, a natural skin barrier that is particularly good for sensitive skin, this powder protects the skin from irritation. Karaya Powder also provides a natural bacteriostatic action and helps prevent skin breakdown. Use sparingly to absorb moisture or exudate from skin prior to applying a skin barrier¹⁵.

It has been used in traditional medicines for 5000 years. It is recognized as safe and non-toxic and used in many products ranging from food emulsifiers, adhesives, laxatives, dentures, lotions, and of course ostomy supplies such as for ileostomy and colostomy and hair dressing preparation lotions as cosmetic purpose^{12,16}. It enhances the epidermal growth as well growth of

granulation tissue thereby used in resistant or chronic bed sores. Gum karaya has some anti-inflammatory and antibacterial characteristics.

There are certain limitations in the present study. The study assessed only the wound healing process. The study will be strengthened if could have done the wound culture. In future,

prospective longitudinal study can be focused with large samples in long duration to identify the side effects of karaya powder application and to determine the reliability and efficacy of the action towards diabetic foot ulcer. In current study no side effects were encountered.

Table 1: Frequency and percentage distribution of clinical variables of patients with diabetic foot ulcer

Clinical variable	Experimental group		Control group	
	No.	%	No.	%
Type of Diabetes Mellitus				
Type I	-	-	-	-
Type II	30	100.00	30	100.00
Duration of DM				
<5 yrs	4	13.33	6	20.00
5-10 yrs	16	53.33	16	53.33
More than 10 yrs	10	33.33	8	26.66
Type of treatment				
Insulin				
Oral Hypoglycemic agent	4	13.33	6	20.00
Both	26	86.66	24	80.00
Peripheral Vascular disease				
Yes	2	6.66	4	13.33
No	28	93.33	26	86.66
Regular follow up treatment				
Yes	30	100.00	30	100.00
No				
Practicing self-care Practice of foot care				
Poor	26	86.66	20	66.66
Good	4	13.33	10	33.33

Table 2: Comparison pre-test and post-test level of wound healing in experimental group

Level of Wound healing of diabetic foot ulcer	Mean	SD	Paired t test
Pre-test	17.6	2.164	t = 14.16
Post-test	13.6	2.44	df=29
			p = 0.001
			S***

***p<0.001, S – Significant

Table 3: Comparison of post-test level of wound healing score among patients with diabetic foot ulcer between the experimental and control group

Wound healing of diabetic foot ulcer	Mean	S.D	Unpaired 't' test
Experimental group Post-test	13.6	2.44	t = 13.146
Control group Post-test	19.6	2.52	df= 28
			p = 0.001
			S

***p<0.001, S – Significant

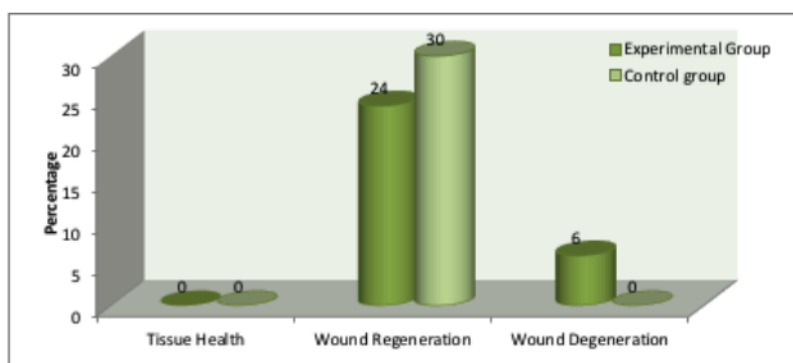


Figure 1: Percentage distribution of pre-test level of wound healing of diabetic foot ulcer among patients with diabetic foot ulcer in the experimental and control group

CONCLUSION

The findings of the present study suggest that karaya powder is effective in improving the level of wound healing. There is no good evidence that one type of dressing is better than another for diabetic foot ulcers. In selecting dressings for chronic non-healing wounds, it is recommended that the cost of the product be taken into account. Therefore, suggest the karaya powder dressing might be applied in other similar situations in diabetic foot ulcer patients so the effects can be evaluated for further improvement. There is a need for more investigation on the action of karaya powder on diabetic foot ulcer.

ACKNOWLEDGEMENT

The authors would like to thank all the patients for participating in this research study and also thank the surgeon and nursing staff of the surgical ward for their support to complete the study successfully.

REFERENCES

1. Lauterbach S, Kostev K, Kohlmann T. Prevalence of diabetic foot syndrome and its risk factors. *J wound care*, 2010; 19(8): 333-337.
2. Katsilambros N, Dounis E, Makrilakis K, Tentolouris N, Tsapogas P. Atlas of the diabetic foot. 2. Oxford: Wiley-Blackwell; 2010.
3. Moxey PW, Gogalniceanu P, Hinchliffe RJ, et al (2008). Lower extremity amputations—a review of global variability in incidence. *Diabetic medicine*, 28:1144–1153.
4. Tesfamichael G, Mariam, Abebaw Alemayehu, Eleni Tesfaye, Worku Mequannt, Kiber Temesgen, Fisseha Yetwale, et al. Prevalence of Diabetic Foot Ulcer and Associated Factors among Adult Diabetic Patients Who Attend the Diabetic Follow-Up Clinic at the University of Gondar Referral Hospital, North West Ethiopia, 2016: Institutional-Based Cross-Sectional Study. *Journal of Diabetes Research*, 2017;2017:1-8.
5. Prompers L, Huijberts M, Apelqvist J, Jude E, Piaggese A, Bakker K, Edmonds M, et al. High prevalence of ischaemia, infection and serious comorbidity in patients with diabetic foot disease in Europe. Baseline results from the Eurodiale study. *Diabetologia*, 2007; 50(1):18-25.
6. Benotmane A1, Mohammedi F, Ayad F, Kadi K, Azzouz A. Diabetic foot lesions: Etiologic and prognostic factors. *Diabetes Metab*, 2000; 26(2):113-7.
7. Kshitij Shankhdhar, Lakshmi Kant Shankhdhar, Uma Shankhdhar, Smita Shankhdhar. Diabetic foot problems in India: An overview and potential simple approaches in a developing country. *Current diabetes report*, 2008; 8(6): 452-457.
8. Jagdev Singh. Medicinal plants: Karaya gum (sterculia gum) uses & benefits. *Ayur times* . 2017.
9. VikasKumar, 2016. https://www.researchgate.net/.../309188064_Gum_karaya_Sterculia_urens_Roxb_A_pot..
10. D Verbeken; S Dierckx; K Dewettinck. *Appl Microbiol Biotechnol*, 2003, 63, 10-21.
11. D Le Cerf; F Irinei; G Muller. *Carbohydrate Polymer*, 1990, 13, 375–386.
12. "Karaya gum". *Natural Medicines Comprehensive Database*. WebMD. Retrieved 2015-01-25.
13. B Singh; L Pal. *European Polymer Journal*, 2008, 44, 3222–3230.
14. Anupama Setia, S. Goyal and N. Goyal. Applications of Gum Karaya in Drug Delivery Systems: A Review on Recent Research. *Der Pharmacia Letter*, 2010, 2(5): 39-48.
15. Hollister Karaya - Powder for Peristomal Skin Protection. <https://www.exmed.net/p-1694-hollister-karaya-powder-for-peristomal-skin-protection..>
16. Kyel Jindel. Origins and uses of karaya gum in ostomy supplies. 2010. *Ezine articles*.

Cite this article as:

Thenmozhi P et al. Karaya powder and its effect on diabetic foot ulcer. *Int. Res. J. Pharm.* 2018;9(10):161-164 <http://dx.doi.org/10.7897/2230-8407.0910245>

Source of support: Nil, Conflict of interest: None Declared

Disclaimer: IRJP is solely owned by Moksha Publishing House - A non-profit publishing house, dedicated to publish quality research, while every effort has been taken to verify the accuracy of the content published in our Journal. IRJP cannot accept any responsibility or liability for the site content and articles published. The views expressed in articles by our contributing authors are not necessarily those of IRJP editor or editorial board members.